SPINE Volume 33, Number 9, pp 973–978
©2008, Lippincott Williams & Wilkins

Endoscopic Transforaminal Discectomy for Recurrent Lumbar Disc Herniation

A Prospective, Cohort Evaluation of 262 Consecutive Cases

Thomas Hoogland, MD, PhD, Karolien van den Brekel-Dijkstra, MD, PhD, Michael Schubert, MD, and Boris Miklitz, BSc

Study Design. A prospective, cohort evaluation of 262 consecutive patients who underwent transforaminal endoscopic excision for recurrent lumbar disc herniation, after previous discectomy.

Objective. To review complications and results of the endoscopic transforaminal discectomy (ETD) for recurrent herniated disc with a 2-year follow-up.

Summary of Background Data. Recurrent herniation is a significant problem, as scar formation and progressive disc degeneration may lead to increased morbidity after traditional posterior reoperation. The studies published until now on recurrent disc herniation concern various operative techniques, mostly the lumbar microdiscectomy, which is still seen as the standard. The advantage of ETD could be that there is no need to go through the old scar tissue and the procedure can be performed in local anesthesia. The disadvantage may be a long learning curve for the surgeon.

Method. Between January 1994 and November 2002, 262 patients with primarily radicular problems underwent an ETD for a recurrent herniated disc. Two hundred and thirty-eight of these patients (90.84%) completed our 2-year follow-up questionnaire. Initial surgery of 82 patients was performed in-house, 180 external. Average age was 46.4 years. The female/male ratio was 29/71%.

Results. At 2-year follow-up 85.71% of patients rated the result of the surgery as excellent or good. 9.66% reported a fair and 4.62% patients an unsatisfactory result. Average improvement of back pain of 5.71 points and 5.85 points of leg pain on the VAS scale (1–10). According to Mac Nab, 30.67% of the patients felt fully regenerated, 50% felt their functional capacity to be slightly restricted, 16.81% felt their functional capacity noticeably restricted, and 2.52% felt unimproved or worse. All patients participated in a 3-month follow-up to establish the perioperative complications. The overall complication rate was 10/262 (3.8%), including 3 nerve root irritations and 7 early recurrent herniations (<3 month). There was no case of infection or discitis.

After 3 months and within 2 years, 4 patients have been treated for a recurrent herniated disc in our own center and 7 patients have been treated elsewhere, resulting in a recurrence rate 11/238 (4.62%).

Conclusion. ETD for recurrent disc herniation seems to be an effective method with few complications and a high patient satisfaction.

Key words: endoscopy, transforaminal discectomy, recurrent disc herniation, lumbar disc herniation, ETD, lumbar spine, recurrence rate. **Spine 2008;33:973–978**

Compression of the neurologic elements of the lumbar spine is a clear indication for surgical decompression. At present, it seems that microdiscectomy is distinguished worldwide as the standard for the decompression of a radicular syndrome caused by disc-herniation.[1,2] The evaluation of the results of disc discectomy is complicated. The primary indication is leg-pain, and besides the complication rate, the absence or improvement of leg-pain is the most important outcome parameter for the patient. The potential increase of back-pain is probably the second most important parameter for the overall satisfaction; therefore, the visual analog scale (VAS) for back pain, VAS for radicular pain and the subjective satisfaction, and judgment of the patient should be the main parameter to rate the result of HNP-surgery.

The rate of revision after a lumbar discectomy is a recognized objective measure of the failure of primary surgery and is included in many outcome studies.[3] A recurrent herniation after a lumbar discectomy has been reported in 5% to 18% of the patients and depends on the duration of the follow-up[1,4–15] (Table 1). Reports of results of recurrent disc herniation requiring repeat operation, however, quote percentages with differences in the length of follow-up and analyzed mixed patient populations, including patients with other diagnoses than a true recurrent disc herniation (for example, spinal stenosis, herniation at a new level, perineural fibrosis, or failed back surgery).[16] Studies on recurrent disc herniation published until now concern various operative techniques, which makes comparison of the effect of these different operations difficult.

Since 1963, new, less invasive decompressive procedures for herniated disc have been developed by the introduction of chymopapain by Smith,[17] later Hijikata and Craig developed the closed percutaneous nucleotomy,[18,19] and in 1987, the percutaneous laser-nucleolyzers have been introduced for the decompression of a lumbar disc-herniation.[20] The technique has been evolved with a transforaminal access to the herniation site,[21] and in addition, endoscopes were introduced to visualize the intraforaminal nerve-root.[13,22–23] In 1994, Hoogland in-

From the Department of Spine Surgery, Alpha Klinik Munich, Germany.
Acknowledgment date: March 24, 2007. Revision date: November 6, 2007. Acceptance date: November 27, 2007.
The manuscript submitted does not contain information about medical device(s)/drug(s).
No funds were received in support of this work. No benefits in any form have been or will be received from a commercial party related directly or indirectly to the subject of this manuscript.
Address correspondence and reprint requests to Dr. Thomas Hoogland, Department of Spine Surgery, Alpha Klinik Effnerstr. 38 81925 Munich; E-mail: hoogland@alphaklinik.de

Table 1. Recurrence Rates Lumbar Discectomy From Literature[1,4–14]

Author	Year	No. Procedures	Follow-up Period	Reoperation (%)
Weir/Jacobs[4]	1980	560	10 yr	11.8
Schuler *et al*[5]	1983	1500	Not specified	6.5
Vik A *et al*[6]	2001	211	8 yr	8.6
Keskimäki *et al*[*7]	2000	25,366	4 yr	12.3
			9 yr	18.9
Hu[*8]	1997	4722	4 yr	9.5
Erbayraktar[*9]	2002	570	1 mo–9 yr	6.5
Yorimitsu[10]	2001	72	10 yr	12.5
Jerosch[11]	1996	846	31 yr	6.3
Morgan-Hough[12]	2003	531	1–16 yr	7.9
Findlay[1]	1998	79	10 yr	5.1
Yeung (ETD)[13]	2002	307	1–1.5 yr	5
Hoogland (ETD)[14]	1999	137	2 yr	5

In some studies various types of reoperations were included.
*Also for other diagnosis as herniated disc.

troduced new instrumentation enabling the enlargement of the foramen with special reamers, so that the anterior spinal canal could be made accessible for endoscope and instruments.[24] At that point, all types of disc herniations became accessible for the lateral-percutaneous approach.

Whether this technique would also be suitable for recurrent herniations was unclear until now. In theory, it would be an advantage not having to go through the old scar tissue and not requiring general anesthesia. Until now, there are only a few small studies available about the applicability of the endoscopic transforaminal discectomy (ETD) for recurrent herniations.[25–27]

It was our objective to assess complications and results of the ETD for recurrent herniated disc with a 2-year follow-up in 238 patients.

Materials

With a prospectively cohort study, we reviewed the data from all patients who underwent an ETD for a recurrent herniated disc in our clinic between January 1, 1994, until November 1, 2002. From the 2717 endoscopic procedures in our center for a herniated lumbar disc in this time period, 322 patients had a recurrent herniated disc; 262 of those patients fulfilled the inclusion criteria. Previous surgery, regardless the type of operation and number of preoperations, had been performed in 82 patients by the senior author and elsewhere in 180 patients (N = 262). Before their rediscectomy, 194 patients had a microscopic disc surgery and 68 patients had had endoscopic spine surgery. The average time interval between the first and the repeat surgery is presented in Table 2.

The average age was 46.4 years (18–80 years). Twenty-nine percent of the patient were female, 71% were male. The preponderance of men is in accordance with other published papers on herniated disc operations.[28] One surgeon carried out all operations. The operated levels are presented in Table 3.

Inclusion criteria were as follows: (1) recurrences that developed as a new lumbar disc herniation with at least a 6-month pain-free interval at the same level, (2) primarily radicular symptoms with an acute onset, (3) signs of nerve entrapment, (4) correlating neurodiagnostic symptoms, and (5) correlating positive MRI-findings.

Table 2. Years Between First (Previous) and Reoperation (Endoscopic)

Operations Interval	No.	Percentage
>6 mo and <2 yr	90	34.35
>2 yr and <5 yr	83	31.67
>5 yr and <10 yr	55	20.99
<10 yr and <20 yr	34	12.98
	N = 262	100

Methods

All patients were treated as a day-case or with 1 overnight stay. All patients underwent a follow-up examination on the next day. The procedure was performed in local anesthesia, intravenous analgesia with opioid medication and 2 to 10 mg midazolam sedation, with the patient lying on the unaffected side on a radiolucent table in the operating suite. The back of the patient was disinfected, and a sterile screen-drape was applied. A biplane fluoroscopy was used for radiograph imaging. Then, the entrance point was determined with a metal rod that was projected with imaging guiding towards the isthmus of the upper lamina of the involved level. Depending on the size of the patient, gender, and level, the entrance point was located at the L5–S1 level at 12 to 16 cm from the midline, at the L4–L5 level at 11 to 14 cm from the midline, at the L3–L4 level 8 to 10 cm from the midline, and at L2–L3 level 7 to 9 cm from the midline. A standard endoscopic transforaminal procedure was performed with widening of the foramen.[29,30] At all times at the end of the procedure, the freed nerve-root could be identified and it always could be visualized that the nerve-root was corresponding with the heart-rate (not with the breathing-rate). Periradicular scar tissue was left undisturbed.

Follow–up

The senior author and surgeon were not involved in patient assignment to the study nor with the evaluation of the questionnaires. All 262 patients had a 3-month follow-up, at which time patients' satisfaction and all complications were registered. In 251 patients, a postoperative MRI at 3 months was evaluated for dural cyst or myelomeningocele. From the total study population of 262 patients who underwent an ETD for a recurrent herniated disc, 238 patients completed the 2-year follow-up questionnaire (response rate 91%). All patients were evaluated respective the following criteria: (a) body capacity rating (according to MacNab,[31] Table 4), (b) leg-pain level according to the 10 point VAS, (c) Back-pain according to the 10 point VAS, (d) subjective patient satisfaction, grading the result of the operation as: excellent, good, fair, or unsatisfied, (e) subjective grading of sensibility disturbances, (f) subjective grading of leg-strength (g) recurrence rate, (h) sport activities grading, and an (i) individual analysis of the complications were added.

Table 3. Number of Operations at the Different Levels of the Lumbar Spine (N = 262)

L2–3	2
L3–4	5
L4–5	137
L5–S1	113
L5–6	5

Table 4. MacNab[31] Classification

Results	Complications
Excellent	No pain; no restriction of activity
Good	Occasional back or leg pain not interfering with the patient's ability to do his or her normal work, or to enjoy leisure activities
Fair	Improved functional capacity, but handicapped by intermittent pain of sufficient severity to curtail or modify work or leisure activities
Poor	No improvement or insufficient improvement to enable an increase in activities/or further operative intervention required

The reasons for noncompliance (24 patients) of the 2-year questionnaire were unknown in 13 cases, 8 had moved without providing a new address, 1 didn't wish to answer any further questionnaires, 1 patient passed away (no relation to his back surgery), 1 patient committed suicide. Of these 24 patients who were not followed up, the subjective satisfaction after 3 months had been 79% (totally) satisfied, 12.5% reported a fair result and 8.5% an unsatisfactory result.

At the 3 months clinical follow-up (N = 262), the peri- and postoperative complications were evaluated via questionnaire, and in 251 cases, a 3-month postoperative magnetic resonance imaging (MRI) was evaluated. None of the 251 MRI studies showed either a dural cyst or myelomeningocele. There were no cases of dural tears or spinal fluid leaks. Three patients reported a postoperative nerve root irritation; in all 3 cases, the compressed transversing nerve root was involved, not the healthy exiting nerve root; 2 were successfully treated with physiotherapy and NSAIDs; 1 lasted for 11 months, despite conservative treatment and disappeared after a nerve block. There were no cases of infection or discitis. Six patients had an early (within 3 months) recurrent lumbar disc herniation (6/262 = 3.44%), 1 patient after 1 day (because he slipped in the shower), 1 patient after 6 days, 1 patient after 12 days, 2 patients after 4 weeks, and 1 patient after 12 weeks. Four patients were reoperated by means of microscopic decompression (3 successfully) and 2 patients were successfully treated with an endoscopic reoperation. However, it is not completely certain that these early cases were persistent nerve compression symptoms from inadequate removal of extruded/protruded disc material. We do not believe that the early cases were recurrences, because intraoperatively in all cases a pulsating freed nerve root was observed; all patients had a negative SLR at the postoperative check up on the next day and all had a pain-free interval, except for the patient that fell in the bathtub.

Two-Year Postoperative Questionnaire Results

Body Capacity Rating According to MacNab[31] (n = 238). Seventy-three patients reported an excellent result with a fully regained body capacity (30.67%), 119 patients reported a good result with minor restrictions (50%), 40 patients reported a fair result with restrictions in their body capacity (16.8%), and 6 patients reported poor results with no or insufficient improvement (2.5%). According to the Mac Nab criteria, a satisfactory result was also registered in 97%.

Leg-Pain After 2 Years (n = 238). An average improvement of leg pain of 5.85 points on the VAS was recorded (from 8.46 preoperative to 2.61 after surgery).

0.004226 + standard deviation pre 1.62 post 2.27

Back-Pain After 2 Years (n = 238). Two hundred and thirty patients recorded an average improvement of their back pain of 5.71 points on the VAS (from 8.56 preoperative to 2.85 after surgery).

0.004226 + standard deviation pre 1.49 post 2.21

Subjective Satisfaction of the Patients (n = 238). Two hundred and four patients reported an excellent or good result (85.71%), 23 patients reported a fair result (9.66%), and 11 patients reported an unsatisfactory result (4.62%) (Figure 1). Of the patients who were unsatisfied, 1 required subsequent microscopic decompression after 6 days, 1 had new complaints after an accident and needed an endoscopic operation in another level, another patient had an microscopic decompression after 1.5 years in our center, 3 patients were treated surgically elsewhere, 3 patients reported that they were still having pain, predominantly leg pain with a restricted or worsened body capacity, and 2 patients didn't indicate any reasons.

Subjective Grading of Sensibility Disturbances (Numbness in the Leg) (n = 141). One hundred and eighteen patients reported there numbness as vanished or better (83.69%), 22 patients reported unchanged results (16.60%), and 1 patient reported that his numbness worsened (0.71%).

Strength in the Leg (n = 111). Ninety seven patients reported that their quadriceps, calf, or foot-extensor-weakness had vanished or significantly improved (87.5%), 13 patients reported unchanged weakness (12%), and 1 patient reported that his calf weakness deteriorated (1%).

Recurrence Rate. Early recurrences within 3 months were considered as postoperative complications and, as such, discussed. Eleven patients have been treated for a (true) recurred herniation after 3 months and within 2 years (recurrence rate, 11/238 = 4.62%), 4 patients were treated in our own center (3 with an ETD plus abrasion and 1 with a microscopic decompression), and 7 patients were treated elsewhere (1 with an ETD, 1 fusion, 5 times microscopic decompression). On average, recurrence occurred at 1.07 years in the 2-year period after rediscectomy surgery.

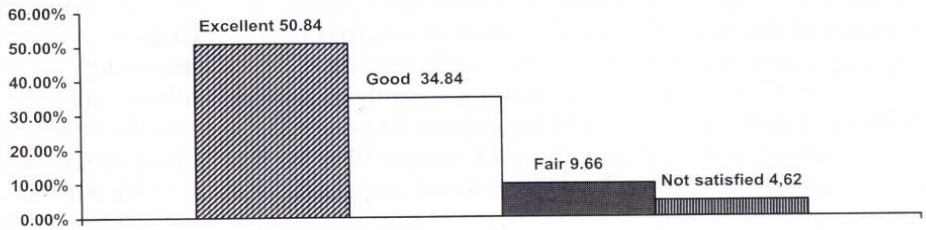

Figure 1. Subjective satisfaction in percentage.

Sport Activity Grading. One hundred and forty four patients participated in recreational sports before the recurrence. After surgery, 158 patients resumed recreational sport activities and 10 patients didn't return to their former sport activities. More than 50% could resume their sportive activities within 3 months. Eighty percent of the patients had returned to their sport activities after 4 months. Sixty-nine percent with the same intensity and frequency they were used to. Twenty-four of the 118 patients who had not been involved in recreational sport activities before their second surgery did take up sports activities after their rediscectomy and 10 of the 144 sport active patients did not resume their sport activities.

Unsatisfied Patients

Of the patients who were unsatisfied, 1 had subsequent microscopic decompression after 6 days, 1 had new complaints after an accident and underwent endoscopic reoperation in another level, another patient had an microscopic decompression (for stenosis) after 1.5 years in our center, 3 patients where treated operatively elsewhere, 3 patients reported that they were still having pain, predominantly leg pain with a restricted or worsened body capacity, and 2 patients didn't report any specific reason for their unsatisfied status.

Discussion

Discussion Outcome Measurement

As Professor Schulitz,[32] a leading spine capacity in Europe, in 2004 wrote in the *European Spine Journal*, in his comment about evaluating standard nucleotomy for lumbar disc herniation, long-term articles are difficult to compare because of the different methods used and because of the lack of initial outcome.[1] He questioned how appropriate the tools of measuring the effectiveness of nucleotomy are. For outcome, he suggested measuring the value of nerve-root decompression 1 to 2 years after the operation, when the healing process in completed. Furthermore, traditional surgical outcome measures of a single rating scale (excellent, good, fair, poor), like MacNab's[31] classification, other authors' personal evaluation scores and various unvalidated questionnaires are no longer sufficient.[33–35] Reliable predictors of surgery outcome are symptoms of leg and back pain VAS and patient satisfaction. Additionally, we tried to evaluate patient satisfaction also by careful registration of their sport activities, and we have demonstrated in this study that more patients were active in sports after surgery than they had been before the recurrence of their herniation.

Scar Tissue/Fibrosis

Many patients and nonsurgeons continue to discuss the role of scar tissue and fibrosis in persistent or recurrent radicular pain after discectomy, but there is no scientific evidence of the role of epidural fibrosis in recurrent sciatica after previous discectomy. However, Jönsson[36] reported prevalence of pain on coughing severely reduced walking capacity and a straight leg raising test less than 30° as indicative of recurrence herniation over fibrosis. It is obvious that the lateral transforaminal approach in ETD bypasses the previous dorsal part of the scar tissue and reduces the risk of dural tears. In our series of 262 patients, no dural tears had to be treated. In 11 cases during the surgery, a spinal fluid leak was suspected, but no treatment was installed, and no dural leaks after surgery occurred or meningoceles or dural cysts in the surgical area were observed in the postoperative MRI scans that were obtained on almost all patients. The incidents of dural tears requiring treatment in dorsal-and microdiscectomy is about 10%.[12] The lateral transforaminal approach creates a working tunnel that leads to the prolapsed or sequestrated disc material. In case of sequestrated or extruded disc material, this is as the first structure in the spinal channel identified at the end of the working cannula that is positioned in the tunnel created by the reamers. This compressing disc material is removable without interference with scar tissue. After removal of the extruded material, the nerve can be inspected and basically old scar tissue laterally and ventrally is left alone. In case of an encapsulated or scar-covered prolapse, the prolapse is perforated underneath the nerve and the prolapsed disc material is removed, until the nerve is decompressed. The ultimate indicator for a sufficiently decompressed nerve with or without more or less scar tissue is the pulsation of the nerve root with the heart rate. This was always observed at the end of the procedure. In comparison, dorsal reintervention requires scar-removal and tedious mobilization and retraction of the compressed nerve root before the offending disc tissue can be reached and removed.

Furthermore, it can be concluded that after lateral ETD the recurrence and extension of postoperative scar tissue is extensively less than in the dorsal techniques.

Comparison With Open, Dorsal-(Micro-) Discectomy

The majority of the spine surgeon community does consider microdiscectomy to be the gold standard operative treatment for lumbar disc herniation, and probably also for recurrent herniation that is not adequately responding to conservative treatment.

In our procedure, we did not specifically deal with fibrosis and always removed protruded, extruded or sequestrated disc material under the compressed/irritated nerve root with video endoscopic documentation. At all times, a widening of the bony part of the foramen up to the spinal canal is performed with the ETD technique (Hoogland-Schubert); therefore, a stenotic compartment was more or less addressed, but the primary goal was the removal of disc material. Nowadays, however, all types of disc-herniations are accessible for the lateral-percutaneous approach with the ETD.[29] Yeung *et al*[13] reported the outcome and complications in 307 cases of posterolateral endoscopic discectomies for primarily HNP with a minimal follow up of 1 year (average follow up was 19 months). They reported an 83.6% excellent and good result and a 9.3% rate of poor results. Their reoperation rate was 5%. These results are comparable with the results in our group of ETD[29] in patients with a primary herniated disc. In this study, we assessed

the efficacy of ETD for recurrent herniations with a success rate of 86%.

So far, only a few small studies have been published about the results of an ETD for a recurrent herniated disc. Ahn *et al*[25] studied retrospectively 43 consecutive patients who got a posterolateral endoscopic laser assisted disc excision for a recurrent herniated disc preoperated with a conventional open discectomy. 81.4% of the patients showed excellent or good outcomes and the VAS decreased significantly, but the study population was small. Le *et al*[27] reported 90% excellent or good results when performing microendoscopic discectomy compared with historical controls in which conventional open surgery. Isaacs *et al* assessed only 10 consecutive patients undergoing microendoscopic rediscectomy prospectively and compared with the previous 25 who underwent routine single-level microendoscopic discectomy, and concluded that this method can be safely performed for recurrent disc herniation without an increase in surgery-related morbidity.

In this study, we demonstrate the good results of the ETD for a recurrent herniated disc with a 2-year follow-up. With an 85.12% excellent or good success-rate, we consider the ETD to be a method with few complications and very suitable for recurrent disc herniations, regardless of the primary procedure was endoscopically or microscopically operated.

Initially it was also our objective to compare our ETD procedure with studies published in the literature for a recurrent herniated disc operated with other techniques like open and microdiscectomy. Unfortunately, the studies available are hard to compare. For example, the study from Jerosch *et al*[11] described also patient satisfaction after a lumbar disc surgery and they reported 40% excellent or good, 40% fair and 20% poor result. However, the follow-up period ranged from 19 until 42 years, different operation techniques have been used in the primary and revision operation and some patients have been reoperated several times. Suk[16] reported on the retrospective results in 28 patients treated by standard open discectomy with a 71% success rate. As this paper was published in *Spine* in 2001, no follow-up period was mentioned and the data probably collected at discharge after surgery. Morgan-Hough[12] reported on open rediscectomies in 42 patients with a 19.1% complication rate including 2 chest-infections after general anesthesia, 14% dural tears, and 1 pseudomeningocele. Jönsson *et al*[36] reported on a 2-year follow up after redecompressions in 19 reherniations, 16 excellent results without specification of the scoring criteria. Haglund[37] reviewed 55 patients retrospectively after second microdiscectomy over a 4-year period and reported 86% complete or partial relieve of all symptoms. In terms of efficacy, the superiority of 1 procedure over the other can only be proven by a multicenter randomized controlled trial. From a practical standpoint, however, such a comparative study does not seem to be feasible.

This study demonstrates that ETD has a good efficacy for recurrent herniated disc, or might even exceed the results of microdiscectomy and most likely results in fewer complications. There seem to be certain advantages of ETD over microdiscectomy:

(1) No need for general anesthesia, (2) less/no cases of iatrogenic neurologic damage, (3) smaller risk of infection, (4) a direct approach to the extruded disc-fragment, (5) only Minimal disturbance of the intracanal capsular structures, and (6) no interference of scar tissue to reach the protruded or extruded recurrent herniated tissue in cases of previous microdorsal-discectomy.

■ Key Points

- Endoscopic transforaminal discectomy carries a very low complication rate.
- Endoscopic transforaminal discectomy seems effective for recurrent disc herniation.
- Endoscopic transforaminal discectomy can successfully be performed in local anesthesia.
- There is a low recurrence rate after endoscopic transforaminal discectomy.

Acknowledgment

We acknowledge Ms. Agnes Ramirez for the preparation of the manuscript.

References

1. Findlay GF, Hall BI, Musa BS, et al. A 10-year follow-up of the outcome of lumbar microdiscectomy. *Spine* 1998;23:1168–71.
2. Saruhashi Y, Mori K, Katsuura A, et al. Evaluation of standard nucleotomy for lumbar disc herniation using the Love method: results of follow-up studies after more than 10 years. *Eur Spine J* 2004;13:626–30.
3. Gaston P, Marshall RW. Survival analysis is a better estimate of recurrent disc herniation. *J Bone Joint Surg Br* 2003;85:535–7.
4. Weir BKA, Jacobs GA. Reoperation rate following lumbar discectomy: an analysis of 662 lumbar discectomies. *Spine* 1980;5:366–70.
5. Schuler P, Clemens D, Rossak K. Nachuntersuchungsergebnisse nach lumbalen Renukleotomien. *Z Orthop* 1983;121:33–6.
6. Vik A, Zwart JA, Hulleberg G, et al. Eight-year outcome after surgery for lumbar disc herniation: a comparison of re-operated and not re-operated patients. *Acta Neurochir* 2001;143:607–10.
7. Keskimäki I, Seitsalo S, Österman H, et al. Reoperations after lumbar disc surgery. *Spine* 2000;25:1500–8.
8. Hu RW, Jaglal S, Axcell T, et al. A Population-based study of re-operations after back surgery. *Spine* 1997;22:2265–70.
9. Erbayraktar S, Acar F, Tekinsoy B, et al. Outcome analysis of reoperations after lumbar discectomies: a report of 22 patients. *Kobe J Med Sci* 2002;48:33–41.
10. Yorimitsu E, Chiba K, Toyama Y, et al. Long-term outcomes of standard discectomy for lumbar disc herniation. *Spine* 2001;26:652–7.
11. Jerosch J, Castro WHM. Langzeitergebnisse von Reoperationen nach lumbalen Nukleotomien. *Z Orthop* 1996;134:89–96.
12. Morgan-Hough CVJ, Jones PW, Eisenstein SM. Primary and revision lumbar discectomy. *J Bone Joint Surg Br* 2003;85:871–4.
13. Yeung AT, Tsou PM. Posterolateral endoscopic excision for lumbar disc herniation: surgical technique, outcome, and complications in 307 consecutive cases. *Spine* 2002;1:27:722–31.
14. Hoogland T, Scheckenbach C, Dekkers H. Endoskopische transforaminale diskektomie. *Ambulant Operieren* 1999;4:1–3.
15. Österman H, Sund R, Seitsalo S, et al. Risk of multiple reoperations after lumbar discectomy: a population-based study. *Spine* 2003;28:621–7.
16. Suk K-S, Lee H-M. Recurrent lumbar disc herniation, results of operative management. *Spine* 2001;26:672–6.
17. Smith L. The development of chemonucleolysis – an overview. In: Sutton JC,

ed. *Current Concepts in Chemonucleolysis*. London, UK: Royal Society of Medicine; 1985;l ff.
18. Hijikata S. Percutaneous nucleotomy: a new concept technique and 12 years experience. *Clin Orthop* 1983;238;9–23.
19. Craig F. Vertebral-body biopsy. J *Bone Joint Surg Am* 1956;38:93–102.
20. Choy DS. Risks of laser discolysis. *J Neurosurg* 1992;77:978.
21. Kambin P, Gellman H. Percutaneous lateral dicscectomy of the lumbar spine: a preliminary report. *Clin Orthop* 1983,174,127–32.
22. Knight M, Goswami A. Management of isthmic spondylolisthesis with posterolateral endoscopic foraminal decompression. *Spine* 2003;28:573–81.
23. Hoogland T. Percutaneous endoscopic discectomy. *J Neurosurg* 1993;79: 967–8.
24. Hoogland T, Hallbauer J. Endoscopical foraminal removal of disc herniation. Presented at the 4th International Spine Symposium, München; 1995.
25. Ahn Y, Lee SH, Park WM, et al. Percutaneous endoscopic lumbar discectomy for recurrent disc herniation: surgical technique, outcome, and prognostic factors of 43 consecutive cases. *Spine* 2004;29 326–32.
26. Isaacs RE; Podichetty V, Fessler RG. Microendoscopic discectomy for recurrent disc herniations. *Neurosurg Focus* 2003;15:E11.
27. Le H, Sandhu FA; Fessler RG. Clinical outcomes after minimal-access surgery for recurrent lumbar disc herniation. *Neurosurg Focus* 2003;15:E12.
28. Spangfort EV. The lumbar disc herniation. *Acta Orthop Scand Suppl* 1972; 142:1–95.
29. Hoogland T, Schubert M, Miklitz B, et al. Transforaminal posterolateral endoscopic discectomy with or without the combination of a low-dose chymopapain: a prospective randomized study in 280 consecutive cases. *Spine* 2006;31:E890–E897.
30. Schubert M, Hoogland T. Die transforaminale endoskopische Nukleotomie mit Foraminoplastik bei lumbalen Bandscheibenvorfällen. Endoscopic Transforaminal Nucleotomy with Foraminoplasty for lumbar disk herniation urban & vogel. *Oper Orthop Traumatolog* 2005;5:641–61.
31. MacNab I. Negative disc exploration. An analysis of the causes of nerve-root involvement. *J Bone Joint Surg Am* 1971,53:891–903.
32. Schulitz K. Comment on "Evaluation of standard nucleotomy after love for lumbar disc herniation: results of follow-up studies after more than 10 years" by Y. Saruhashi et al. *Eur Spine J* 2004;13:631–32.
33. Deyo RA, Battie M, Beurskens AJ, et al. Outcome measures for low back pain research. *Spine* 1998;23:2003–13.
34. Howe J, Frymoyer J. Effects of questionnaire design on determination of end results in lumbar spine surgery. *Spine* 1985;10:804–5.
35. Kopec J. Measuring functional outcome in persons with back pain. A review of back-specific questionnaires. *Spine* 2000;25:3110–14.
36. Jönsson B, Strömqvist B. Clinical characteristics of recurrent sciatica after lumbar discectomy. *Spine* 1996;21:500–5.
37. Haglund M, Moore A, Marsh H, et al. Outcome after repeat lumbar microdiscectomy. *Br J Neurosurg* 1995;9:487–95.